

Endobutton Technique and its Outcomes in Surgical Treatment of Acromioclavicular Joint Dislocation: A Review Article

Gopal Prasad Yadav, Wu Hao, Ji Ming Liang, Lu Jun*

Department of Orthopedics, The Affiliated Zhong Da Hospital of Southeast University, No. 87 Dingjiaqiao, Nanjing, China.

Abstract

Acromioclavicular joint dislocation is one of the common problems among young athletes. A gold standard technique for AC-joint separation is still awaited. The current techniques being used these days fail to manage the anatomical structure and biomechanical functions in AC-joint separation. Recently, hardware being used led to high risk of failure with slippage of the initial reduction. Nowadays, recent researches reported a novel technique for the treatment of shoulder AC-joint dislocation by endobutton CL. This review highlights a new approach called endobutton technique and its outcomes in the surgical treatment of acromioclavicular joint dislocation. Endobutton CL material is found with both the strength and actual anatomy assistance for a stable reduction. This surgical technique is minimal invasive, simple, and proved to be a safe and effective for reconstruction of AC-joint. The use of endobutton in AC-joint dislocation is very consistent and have no complication associated with minimal blood loss along with the level of pain decreased as compared to other techniques.

Keyword: Endobutton, acromioclavicular joint, coracoclavicular ligament, AC-joint separation.

Received February 13, 2017; **Revised** March 26, 2017; **Accepted** April 5, 2017

***Correspondence:** Lu Jun, **Email** lujun@medmail.com.cn, **Contact:** +8613813389966

To cite this manuscript: Yadav GP, Hao W, Liang JM, Jun L. Endobutton Technique and its outcomes in surgical treatment of acromioclavicular joint dislocation: A review article. *Biomed Lett* 2017; 1(1): 60-65.

Introduction

Dis-joining of AC-joint is one of the most common shoulder dislocation seen especially among active individuals and athletes. According to Rockwood classification, AC-joint injury classified into type I-VI on the basis of radiographic findings [1, 2]. Non-operative treatments are recommended for Rockwood I and II type separations, while the management of Rockwood III dislocation still remains controversial. Rockwood IV and above-mentioned type of dislocations require operative treatment for adequate reduction and stabilization [3, 4]. Without surgical intervention, biomechanical and cosmetics, injuries would be permanent [5-7].

Although the various type of surgical methods are used to treat AC joint dislocation in old time, there is still wait for gold standard technique [8-10]. Techniques using different kinds of hardware fixation, like the Bosworth screw, K-wire, and Hook plate have disapproval due to problems arising from implant failure, unsatisfactory maintenance of reduction and requirement for a second-time surgery to remove the implant [11]. In recent time, several procedures recommended for CC ligament repair like Weaver-Dunn procedure, biological graft, synthetic ligament, anchor suture technique shows significant rates failure among old procedures such as the Weaver-Dunn could be attributed to the extra

feasibility of the reconstructed ligament with respect to the natural ligament [3]. In recent time most utilized technique for an AC-joint dislocation is hook plate and endobutton but hook plate technique has been stopped due to it has complications like implant failure, large incision, and second-time surgery. Some CC ligament reconstruction surgery described before but the strength of ligament is very weak as compare with native ligament leading to reported high failure rate [12].

As of late, the endobutton technique has been elucidated for the treatment of complete AC-joint dislocation [13]. This technique allows the maximum possibility to reconstruct the coracoclavicular ligament in its anatomical position. The clinical outcome is much better than the previous technique. The endobutton technique especially utilized for chronic AC-joint dislocation to achieve biological reconstruction of CC and CA ligament [14]. The complications include for endobutton technique are commonly coracoid fracture, deficiency of soft tissue, constricting coracoid and possibility of infection [15]. This kind of implant demands an uninjured cortex to give stable fixation. The idea of endobutton fixation technique is rather good and very powerful intra-operative fixation help further stabilization of shoulder (15). The technique has an

excellent outcome and validated for biomechanical study with no risk of knot slip and no any second surgery of implant removal [16]. This review introduces a novel surgical technique for reconstruction of coracoclavicular ligament utilizing endobutton, closed loop and five strands of two ethibond suture.

Anatomy of AC-joint

The AC-joint contains the distal end of the clavicle and medial aspect of acromion with introducing fibrocartilaginous disc in the joint. There are four anterior, posterior, superior and inferior ligament strengthened to the acromioclavicular capsule [17]. Posterior and superior ligaments are stronger ligament which helps along with AC capsule to the anterior-posterior stability of the AC-joint. CC ligament laterally situated to the trapezoid ligament and medially to the conoid ligament. The CC ligament called as native ligament of the shoulder which helps to prevent superior-inferior displacement of clavicle [18].

Mechanism of AC-joint Injury

The AC-joint dislocation generally refers to straight blow of shoulder on lateral facet with the arm in an adducted posture leading to the downward displacement of scapula opposed by the clavicle onto the first rib [19, 20]. The direct force on shoulder causes downward acromion associated with CA ligament injuries. Further strength transmitted to the CC ligament leading to the clavicle displacement and a major injury caused by more energy transmitted in deltoid and trapezius muscle resulting herniation to the lateral end of clavicle [21].

Surgical Technique

Different type of surgical technique describe in past time but there is no any clear statement among these techniques [18]. In a very early time of period, fixation technique like K-wire, Steinman pin were described but this kind of fixation make intra-articular surface injury and joint arthritis. Because of CC-ligament disregard, K-wire fixation failure is common and finally stop to use K-wire for AC- joint dislocation [13].

Bosworth screw

Bosworth screw fixes between coracoid and clavicle to get stabilization of AC-joint dislocation. Because of mobility between coracoid and clavicle, weakness of the implant happens over time results drop-off joint mobility and increased joint contact pressure

[22]. The implant failure present as clavicle osteolysis, implant failure and fracture of CC and clavicle. Bosworth screw has been reported maximum chances of implant failure [23].

Weaver-Dunn procedure

The weaver-dunn procedure was first described in 1972, This procedure includes the release of CA ligament from acromion to the replacement of injured coracoclavicular ligament, resection of the distal end of clavicle then the transfer of the coracoacromial ligament to the lateral end of the clavicle, nearly replicating the coracoclavicular ligament [24]. This procedure has been so many modifications and studies show only 25% stronger as compare with native ligament [25]. The native CC ligament placed at the exactly base of the coracoid whereas CA ligament attached to distally and laterally.

Hook plate

The hook plate primarily configured for lateral clavicle fracture but later on drawn-out for AC-joint dislocation [18]. This kind of surgery has been many kinds of complication including acromial osteolysis, implant failure and obvious disadvantage of revision surgery for implant removal (**Figure 1**). Even though so many complications of this surgery but surgeon still prefer this technique because of a low grade of pain, minimal invasive, least postoperative complication and achieved the highest reduction of AC-joint dislocation [24].

Endobutton Technique

The surgical procedure was performed under GA with beach chair posture. L-kind of Incision is made distance the AC-joint to the proximal end of cc-process, trapezius and deltoid fascia are opened transversely. Deltoid is dissected anterior-superiorly clavicle to exposing AC-joint, distal 1/3 of clavicle and base of cc-process [14]. The minimum reduction of the clavicle was made by direct pressure and maintained with K-wire. The axillary view identifies a reduction of ac-joint and no anteroposterior displacement of the clavicle. The superior surface of the clavicle is drilled by guide wire about 3cm medial to the AC-joint. After the confirming guide wire is well centered between the medial and lateral edge of CC, drilling continues till the base of CC (**Figure 2**). The drilling rim about 4mm used over the guide wire and another hole made 2cm from the distal end of clavicle [26]. The appropriate size of endobutton chosen with 5 strands of #2 ethibond suture was placed through the 1st and 4th hole of endobutton.

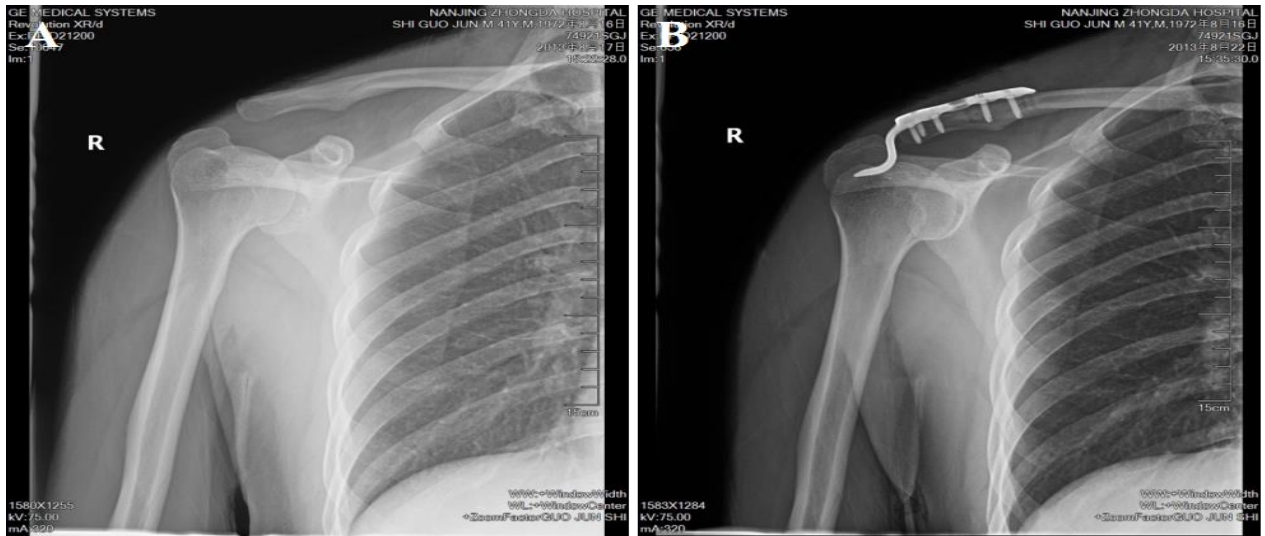


Figure 1: Pre (A) and post (B) operative image finding of 41y male pt. of Rt. AC-joint dislocation for hook plate fixation shows reduction of Rt. AC-joint (B).

Then endobutton is pushed with the help of cylindrical plunger the endobutton is afterward tumbled and its fixation is tested by pulling the free ends. The free end of fiber wires then passes through the two drill holes in the clavicle with needle and thread through each endobutton individually [3]. The suture was tied on the top of endobutton and reduction is achieved by push down clavicle and elevate the arm.

Compare to all of the above method endobutton technique is more popular and handy in recent time because of minimal invasive surgery [21], minimal blood loss, low-grade pain, get original anatomical structure, achieved appropriate reduction and most important there is no any second-time revision

surgery for plant removal.

Clinical Outcomes of Endobutton Technique

The advantage of endobutton technique of AC-joint injuries are its nonrigid anatomical fixation and satisfactory shoulder functional score. Regarding the radiography finding reduction was maintained and achieved successfully [3]. Low level of pain, minimal invasive surgery, and less possibility of ongoing infection lead to endobutton technique for an AC-joint dislocation is the essential choice of treatment. On the basis of shoulder functional score [24], Endobutton technique is more suitable on regarding range of motion and daily lifestyle compares to other technique described before.

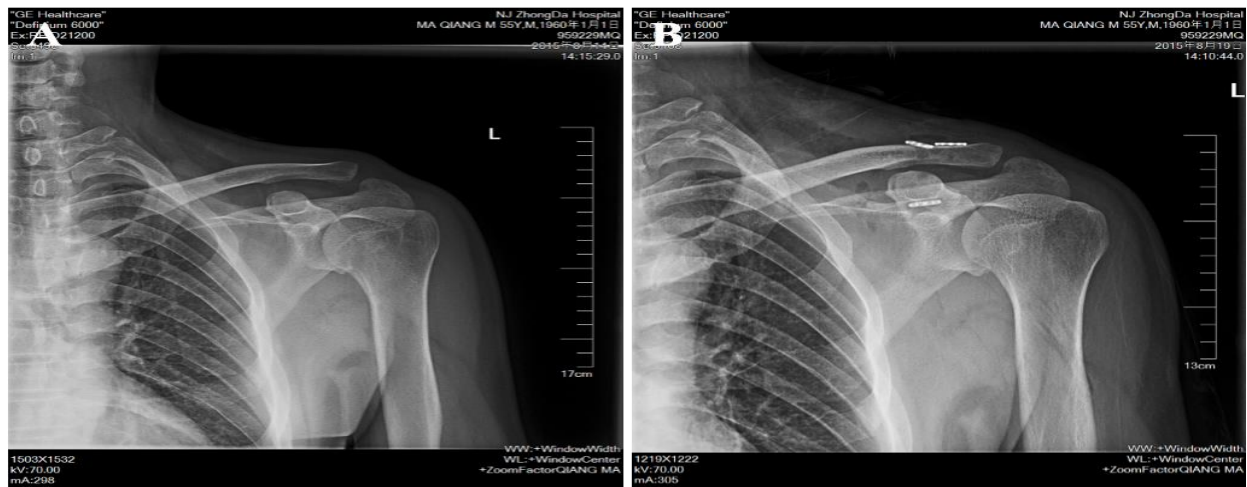


Figure 2: Pre (A) and post (B) operative image of 55y male pt. of Lt. AC-joint dislocation for endobutton technique shows reduction of Lt. AC-joint (B).

Discussion

The most common AC-joint injuries are associated with an athletic population[27], about 9% of shoulder injuries involve damage to the acromioclavicular joint [28] and about 40% of contact sport related injuries[29, 30]. In recent days there are many types of surgical technique have been described to treat AC-joint injuries, in earlier days K-wire was recommended for the fixation of AC joint disjunction affirming its accessibility to operating, low cost and solid firmness. But they have been found complication like damage articular surface and fibrocartilage [31], affect the rotation of clavicle and limitation of upper arm lifting. Even the studies show significant complication in 25%cases of K-wire fixation, including damage to surrounding soft tissues and traumatic arthritis post operation [32]. It can also extend to pin-tail infection and loosening, breaking and prolapse of K-wire, resulting in fixation failure lead to the elimination of single application of K-wire [32].

The fixation of compression screws between coracoid and clavicle is fixed fixation which blocked the range of motion and motility of scapula and clavicle taken over the loosening of screw frequently occurs. Thus compression screw fixation has been completely eliminated [33]. Plenty of hardware used in surgical treatment has shown good results in recent times [34]. Most of them have been related to complications of implant failure, weakening, and trauma [1, 35]. Nowadays AC-joint repair with hook plate fixation is very demanding because of AC joint reduction is kept up in all level and curative extremely good with early mobilization. The drawbacks of this technique were revision surgery to remove the implant associated with shoulder pain, sub-acromial impingement, loosening and unhooking, limited range of motion and fracture distal to the plate [1, 36].

All the above surgical method cannot reconstruct the anatomic structure and function of the CC and AC ligament due to non-anatomical repair [37]. The suture-button technique first invented in 2006 has been validated on biomechanical testing. The clinical result, however, has been fluctuating with the loss of reduction seen in 31% to 50% of cases [5] and fixation failure rate has ranged from 28 to 43% [38-40]. In 2007, Struhl first introduces the good effect of the reconstruction of complete CC ligament using an endobutton. Due to the use of endobutton technique reconstruction of CC ligament and fixation of the AC-joint make possible to allow the freedom for

normal clavicular rotation and range of motion. Experimental studies have been found that according to the magnitude and direction of the forces apply on CC ligament are two-component with different functions [2, 41]. The ideal surgical technique for complete AC dislocation would reconstruct individually all ligament which supporting the AC-joint to range a functionally maximum result. In the previous study, the location of making a hole on the upper side of the clavicle and the placement of reconstructed ligaments were chosen to match the anatomical attachment of coronoid and trapezoid ligament to achieve the anatomical structure of CC ligament [42, 43].

In addition, the double endobutton fixation has been reestablished a biological connection between coracoid and clavicle with either repair of the injured CC ligament or an AC ligament transfer [12, 44]. Although these tissues have the advantage of being vascularized and inherently weak structurally and marginally to initial stability as they are protected from the load by the endobutton implant, recreating this biological CC link may contribute to the healing response and long-term stability [5]. In comparison, the double endobutton fixation commercially reduces the cost of surgery with respect to the triple endobutton fixation. A coalition of the no.5 ethibond suture with endobutton secure adequate mechanical strength for fixation [8]. The deforming forces of the weight of the arm are distributed on the surface of the endobutton and suture plates itself, those passes through the hole of the endobutton. This kind of design protects the suture from slicing through the clavicle when extreme forces are applied [5]. Therefore low profile of the implant reduces the chance of soft tissue reaction and eliminates the obligation of following surgery for implant removal.

Conclusion

Endobutton technique in AC-joint dislocation is one of the reliable technique to restore structure and function of AC-joint. The use of endobutton in AC-joint dislocation is very consistent and have no complication associated with minimal invasive surgery and minimal blood loss along with the level of pain decreased as compared to other techniques. Endobutton is an effective technique for athletic population and active and hardworking patients. By using endobutton CL technique, the anatomical structure and reduction for an AC-joint dislocation is better than the previous techniques such as hook plate and K-wire. Additionally, this technique is simple,

effective, safe and minimal invasive to reconstruct the AC-joint. The endobutton technique is still as a novel technique to treat AC-joint dislocation as far as there is no gold standard technique achieved to treat AC-joint dislocation.

References

- [1] Gstettner C, Tauber M, Hitzl W, Resch H. Rockwood type III acromioclavicular dislocation: surgical versus conservative treatment. *Journal of shoulder and elbow surgery*. 2008;17:220-5.
- [2] Abrams GD, McGarry MH, Jain NS, Freehill MT, Shin SJ, Cheung EV, et al. Biomechanical evaluation of a coracoclavicular and acromioclavicular ligament reconstruction technique utilizing a single continuous intramedullary free tendon graft. *Journal of shoulder and elbow surgery*. 2013;22:979-85.
- [3] Wei HF, Chen YF, Zeng BF, Zhang CQ, Chai YM, Wang HM, et al. Triple endobutton technique for the treatment of acute complete acromioclavicular joint dislocations: preliminary results. *International orthopaedics*. 2011;35:555-9.
- [4] Arirachakaran A, Boonard M, Piyapittayanun P, Phiphobmongkol V, Chaijenkij K, Kongtharvonskul J. Comparison of surgical outcomes between fixation with hook plate and loop suspensory fixation for acute unstable acromioclavicular joint dislocation: a systematic review and meta-analysis. *European journal of orthopaedic surgery & traumatology : orthopedie traumatologie*. 2016;26:565-74.
- [5] Struhl S, Wolfson TS. Continuous Loop Double Endobutton Reconstruction for Acromioclavicular Joint Dislocation. *The American journal of sports medicine*. 2015;43:2437-44.
- [6] Schlegel TF, Burks RT, Marcus RL, Dunn HK. A prospective evaluation of untreated acute grade III acromioclavicular separations. *The American journal of sports medicine*. 2001;29:699-703.
- [7] Rasmont Q, Delloye C, Bigare E, Van Isacker T. Is conservative treatment still defensible in grade III acromioclavicular dislocation? Are there predictive factors of poor outcome? *Acta orthopaedica Belgica*. 2015;81:107-14.
- [8] Pan Z, Zhang H, Sun C, Qu L, Cui Y. Arthroscopy-assisted reconstruction of coracoclavicular ligament by Endobutton fixation for treatment of acromioclavicular joint dislocation. *Archives of orthopaedic and trauma surgery*. 2015;135:9-16.
- [9] Di Francesco A, Zoccali C, Colafarina O, Pizzoferrato R, Flamini S. The use of hook plate in type III and V acromio-clavicular Rockwood dislocations: clinical and radiological midterm results and MRI evaluation in 42 patients. *Injury*. 2012;43:147-52.
- [10] Wellmann M, Zantop T, Petersen W. Minimally invasive coracoclavicular ligament augmentation with a flip button/polydioxanone repair for treatment of total acromioclavicular joint dislocation. *Arthroscopy : the journal of arthroscopic & related surgery : official publication of the Arthroscopy Association of North America and the International Arthroscopy Association*. 2007;23:1132 e1-5.
- [11] Yang YG, Cai XB, Wang XM, Zhu YG, Pan HY. [Case-control study on shoulder pain caused by hook palte for the treatment of acromioclavicular joint dislocation]. *Zhongguo gu shang = China journal of orthopaedics and traumatology*. 2015;28:491-5.
- [12] Assaghir YM. Outcome of exact anatomic repair and coracoclavicular cortical lag screw in acute acromioclavicular dislocations. *The Journal of trauma*. 2011;71:E50-4.
- [13] Mazzocca AD, Arciero RA, Bicos J. Evaluation and treatment of acromioclavicular joint injuries. *The American journal of sports medicine*. 2007;35:316-29.
- [14] Lu D, Wang T, Chen H, Sun LJ. A comparison of double Endobutton and triple Endobutton techniques for acute acromioclavicular joint dislocation. *Orthopaedics & traumatology, surgery & research : OTSR*. 2016;102:891-5.
- [15] Kayaalp ME, Seker A. Acromioclavicular Joint Separation. *The New England journal of medicine*. 2017;376:e1.
- [16] Jensen G, Katthagen JC, Alvarado LE, Lill H, Voigt C. Has the arthroscopically assisted reduction of acute AC joint separations with the double tight-rope technique advantages over the clavicular hook plate fixation? *Knee surgery, sports traumatology, arthroscopy : official journal of the ESSKA*. 2014;22:422-30.
- [17] Boutsiadis A, Baverel L, Lenoir H, Delsol P, Barth J. Arthroscopic-assisted Acromioclavicular and Coracoclavicular Ligaments Reconstruction for Chronic Acromioclavicular Dislocations: Surgical Technique. *Techniques in hand & upper extremity surgery*. 2016;20:172-8.
- [18] Babhulkar A, Pawaskar A. Acromioclavicular joint dislocations. *Current reviews in musculoskeletal medicine*. 2014;7:33-9.
- [19] Cisneros LN, Reiriz JS. Management of chronic unstable acromioclavicular joint injuries. *Journal of orthopaedics and traumatology : official journal of the Italian Society of Orthopaedics and Traumatology*. 2017.
- [20] Dias JJ, Gregg PJ. Acromioclavicular joint injuries in sport. Recommendations for treatment. *Sports medicine (Auckland, NZ)*. 1991;11:125-32.
- [21] Lemos MJ. The evaluation and treatment of the injured acromioclavicular joint in athletes. *The American journal of sports medicine*. 1998;26:137-44.
- [22] Jari R, Costic RS, Rodosky MW, Debski RE. Biomechanical function of surgical procedures for acromioclavicular joint dislocations. *Arthroscopy : the journal of arthroscopic & related surgery : official publication of the Arthroscopy Association of North America and the International Arthroscopy Association*. 2004;20:237-45.
- [23] Thiel E, Mutnal A, Gilot GJ. Surgical outcome following arthroscopic fixation of acromioclavicular joint disruption with the tightrope device. *Orthopedics*. 2011;34:e267-74.
- [24] Metzloff S, Rosslenbroich S, Forkel PH, Schliemann B, Arshad H, Raschke M, et al. Surgical treatment of acute acromioclavicular joint dislocations: hook plate versus minimally invasive reconstruction. *Knee surgery, sports traumatology, arthroscopy : official journal of the ESSKA*. 2016;24:1972-8.
- [25] Saccomanno MF, C DEI, Milano G. Acromioclavicular joint instability: anatomy, biomechanics and evaluation. *Joints*. 2014;2:87-92.
- [26] Beitzel K, Obopilwe E, Chowaniec DM, Niver GE, Nowak MD, Hanypsiak BT, et al. Biomechanical comparison of arthroscopic repairs for acromioclavicular joint instability: suture button systems without biological augmentation. *The American journal of sports medicine*. 2011;39:2218-25.
- [27] Flik K, Lyman S, Marx RG. American collegiate men's ice hockey: an analysis of injuries. *The American journal of sports medicine*. 2005;33:183-7.
- [28] Spoliti M, De Cupis M, Via AG, Oliva F. All arthroscopic stabilization of acute acromioclavicular joint dislocation with fiberwire and endobutton system. *Muscles, ligaments and tendons journal*. 2014;4:398-403.
- [29] Baek SH, Oh CW, Wallace WA, Jeon IH. Anterior clavicle dislocation associated with acromioclavicular dislocation in a soccer player: a case report. *The American journal of sports medicine*. 2007;35:1752-5.
- [30] Torrens C, Mestre C, Perez P, Marin M. Subcoracoid dislocation of the distal end of the clavicle. A case report. *Clinical orthopaedics and related research*. 1998:121-3.
- [31] Hrabakova L, Koloniuk I, Petrzik K. Phomopsis longicolla RNA virus 1 - Novel virus at the edge of myco- and plant viruses. *Virology*. 2017;506:14-8.
- [32] Verdano MA, Pellegrini A, Zanelli M, Paterlini M, Ceccarelli F. Modified Phemister procedure for the surgical treatment of Rockwood types III, IV, V acute acromioclavicular joint dislocation. *Musculoskeletal surgery*. 2012;96:213-22.
- [33] Eberle C, Fodor P, Metzger U. [Hook plate (so-called Basser plate) or tension banding with the Bosworth screw in complete acromioclavicular dislocation and clavicular fracture]. *Zeitschrift fur Unfallchirurgie und Versicherungsmedizin : offizielles Organ der Schweizerischen Gesellschaft fur Unfallmedizin und Berufskrankheiten = Revue de traumatologie et d'assicurologie : organe officiel de la Socie*. 1992;85:134-9.

- [34] Chernchujit B, Tischer T, Imhoff AB. Arthroscopic reconstruction of the acromioclavicular joint disruption: surgical technique and preliminary results. Archives of orthopaedic and trauma surgery. 2006;126:575-81.
- [35] Calvo E, Lopez-Franco M, Arribas IM. Clinical and radiologic outcomes of surgical and conservative treatment of type III acromioclavicular joint injury. Journal of shoulder and elbow surgery. 2006;15:300-5.
- [36] Nadarajah R, Mahaluxmivala J, Amin A, Goodier DW. Clavicular hook-plate: complications of retaining the implant. Injury. 2005;36:681-3.
- [37] Luis GE, Yong CK, Singh DA, Sengupta S, Choon DS. Acromioclavicular joint dislocation: a comparative biomechanical study of the palmaris-longus tendon graft reconstruction with other augmentative methods in cadaveric models. Journal of orthopaedic surgery and research. 2007;2:22.
- [38] Salzmman GM, Walz L, Buchmann S, Glabgly P, Venjakob A, Imhoff AB. Arthroscopically assisted 2-bundle anatomical reduction of acute acromioclavicular joint separations. The American journal of sports medicine. 2010;38:1179-87.
- [39] Kraus N, Haas NP, Scheibel M, Gerhardt C. Arthroscopically assisted stabilization of acute high-grade acromioclavicular joint separations in a coracoclavicular Double-TightRope technique: V-shaped versus parallel drill hole orientation. Archives of orthopaedic and trauma surgery. 2013;133:1431-40.
- [40] Venjakob AJ, Salzmman GM, Gabel F, Buchmann S, Walz L, Spang JT, et al. Arthroscopically assisted 2-bundle anatomic reduction of acute acromioclavicular joint separations: 58-month findings. The American journal of sports medicine. 2013;41:615-21.
- [41] Debski RE, Parsons IM, 3rd, Fenwick J, Vangura A. Ligament mechanics during three degree-of-freedom motion at the acromioclavicular joint. Annals of biomedical engineering. 2000;28:612-8.
- [42] Renfree KJ, Riley MK, Wheeler D, Hentz JG, Wright TW. Ligamentous anatomy of the distal clavicle. Journal of shoulder and elbow surgery. 2003;12:355-9.
- [43] Deveci A, Firat A, Yilmaz S, Yildirim AO, Acar HI, Unal KO, et al. Acromioclavicular reconstruction using hook plate and anterior tibial tendon allograft with triple tunnel: The early results of revision surgery using a novel surgical technique. International journal of shoulder surgery. 2013;7:132-8.
- [44] Al-Ahaideb A. Surgical treatment of chronic acromioclavicular joint dislocation using the Weaver-Dunn procedure augmented by the TightRope(R) system. European journal of orthopaedic surgery & traumatology : orthopedie traumatologie. 2014;24:741-5.